

vet. Maria Cecilia Ricart

endovete@gmail.com
15.5837.9215

Date: 05-17-2018

Requesting Professional: Dr. Hall, Pablo

Owner: M.A

Patient:

Name: UMA Species: Canine Breed: Labrador Sex: female Age: 10 years and 10 months Study
performed: Laryngotracheobronchoscopy Practice
performed: laryngeal prosthesis placement.

Study report:

Laryngoscopy:

Mobility: laryngeal paralysis (this was evaluated with a laryngoscope with the minimum anesthetic plane in inspection was accomplished).

Structure: preserved arytenoid cartilages. Exuberant scarring in the vocal cord area (cordectomy performed approximately 1 month and a half ago). Subglottic stenosis.

Tracheobronchoscopy:

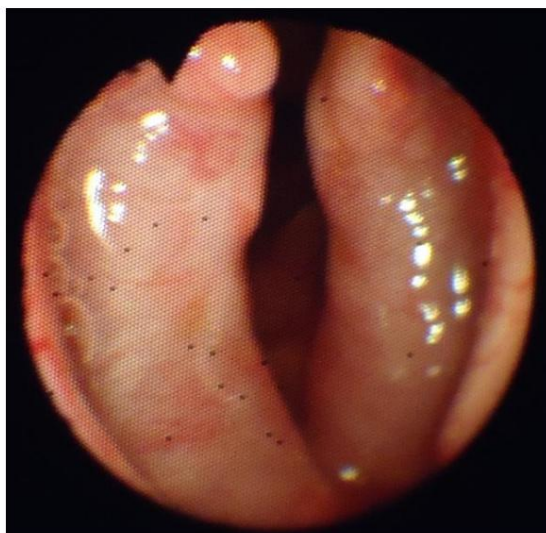
Mild hyperemia of the tracheal mucosa is observed throughout its trajectory. normal face. Compression dorsal extrinsic left cranial bronchus that compresses approximately 25% of the lumen.

With the consent of the family and the referring colleague, a silicone prosthesis is placed on cords. It is explained that it is an experimental procedure, the possible complications expected from the therapy; the family agrees understanding the risks.

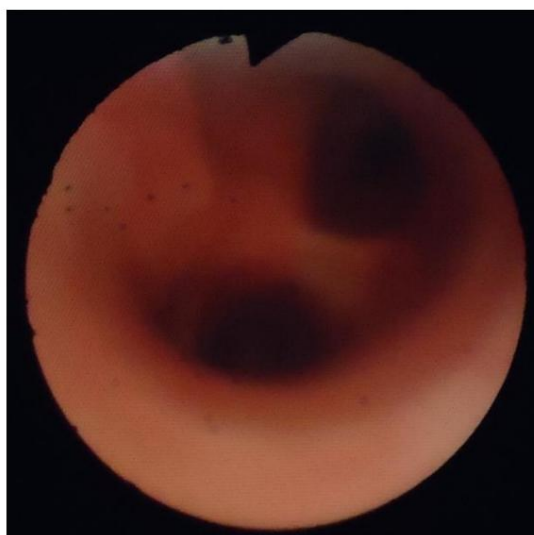The patient recovered without immediate complications: stridor was not perceived.



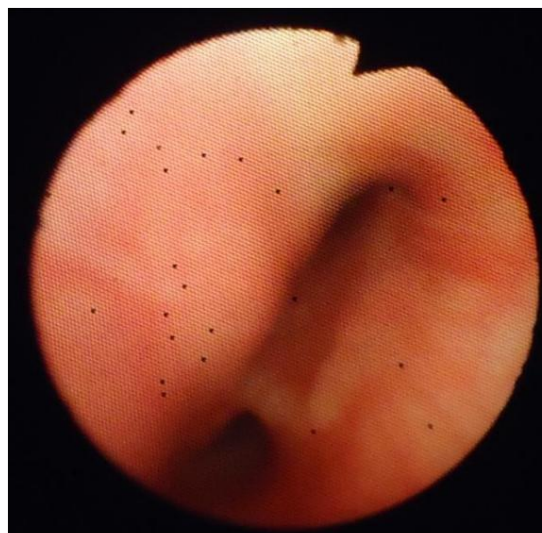
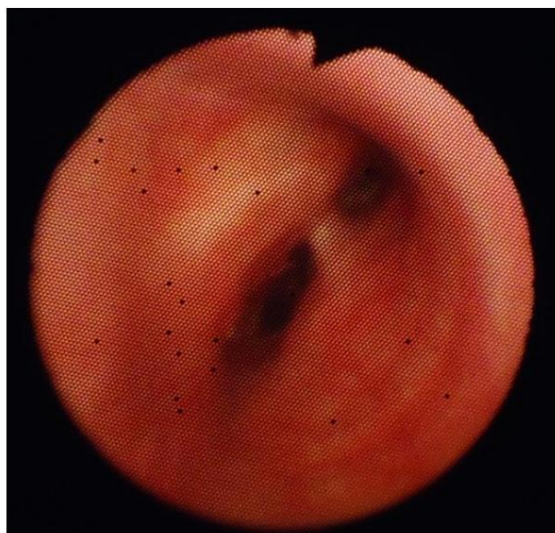
Some photos are attached:



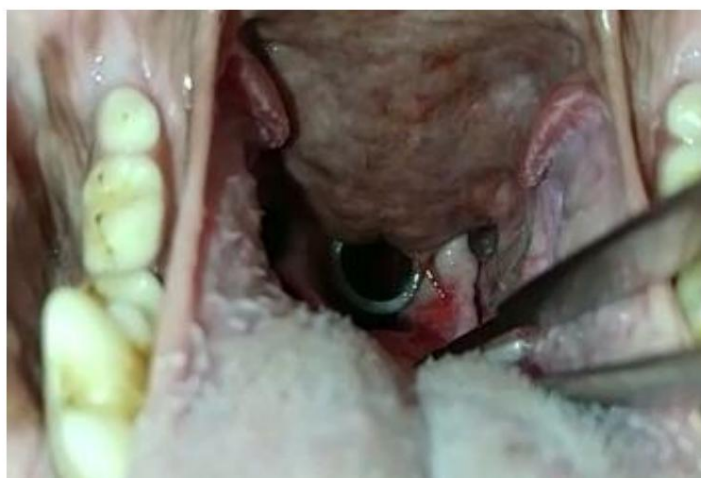Cicatrizacion



Carina



left cranial bronchus



Stening® stent placed

Sincerely,

vet. Ma. Cecilia Ricart

MN 8659